

## ORIGINAL ARTICLE

# Dynamic surgical anatomy using 3D reconstruction technology in complex hepato-biliary surgery with vascular involvement. Results from an international multicentric survey

Christian Cotsoglou<sup>1</sup>, Stefano Granieri<sup>1</sup>, Serena Bassetto<sup>2</sup>, Vincenzo Bagnardi<sup>3</sup>, Raffaele Pugliese<sup>4</sup>, Gian Luca Grazi<sup>5</sup>, Alfredo Guglielmi<sup>6</sup>, Andrea Ruzzenente<sup>6</sup>, Luca Aldrighetti<sup>7</sup>, Francesca Ratti<sup>7</sup>, Luciano De Carlis<sup>8,9</sup>, Riccardo De Carlis<sup>8,10</sup>, Leonardo Centonze<sup>8,11</sup>, Nicola De Angelis<sup>12</sup>, Riccardo Memeo<sup>13</sup>, Antonella Delvecchio<sup>13</sup>, Emanuele Felli<sup>14</sup>, Francesco Izzo<sup>15</sup>, Andrea Belli<sup>15</sup>, Renato Patrone<sup>15,16</sup>, Giuseppe Maria Ettorre<sup>17</sup>, Giammauro Berardi<sup>17</sup>, Fabrizio Di Benedetto<sup>18</sup>, Stefano Di Sandro<sup>18</sup>, Fabrizio Romano<sup>19</sup>, Mattia Garancini<sup>19</sup>, Mauro Alessandro Scotti<sup>19</sup>, Giorgio Bianchi<sup>20</sup>, Alessandro Germini<sup>1</sup>, Elson Gjoni<sup>1</sup>, Alessandro Bonomi<sup>21</sup>, Federica Bruno<sup>1</sup>, Sissi Paleino<sup>1</sup> & Giacomo Pugliese<sup>4</sup>

<sup>1</sup>ASST-Brianza, Vimercate Hospital, Via Santi Cosma e Damiano 10, 20871, Vimercate, <sup>2</sup>Politecnico di Milano, Scuola di Ingegneria Industriale e Dell'informazione, Via Raffaele Lambruschini, 15, 20156, <sup>3</sup>Department of Statistics and Quantitative Methods, University of Milan-Bicocca, Via Bicocca Degli Arcimboldi 8, 20126, <sup>4</sup>AIMS Academy Clinical Research Network, Advanced International Mini-Invasive Surgery (AIMS) Academy, <sup>5</sup>Hepato-bilio-pancreatic Surgery, Department of Experimental and Clinical Medicine, AOU Careggi, 50134, Florence, <sup>6</sup>Department of Surgery, Dentistry, Gynecology and Pediatrics, Division of General and Hepato-Biliary Surgery, University of Verona, P. le L.A. Scuro 10, 37134, Verona, <sup>7</sup>Hepatobiliary Surgery Division, IRCCS San Raffaele and Vita-Salute University, Via Olgettina 60, 20132, <sup>8</sup>Department of Transplantation, Division of General Surgery and Transplantation, ASST Grande Ospedale Metropolitano Niguarda, <sup>9</sup>Department of Medicine and Surgery, University of Milano-Bicocca, <sup>10</sup>Ph.D. Course in Clinical and Experimental Sciences, University of Padua, Padua, <sup>11</sup>Clinical and Experimental Medicine PhD Program, University of Modena and Reggio Emilia, Modena, Italy, <sup>12</sup>Unit of Colorectal and Digestive Surgery, DIGEST Department, Beaujon University Hospital, AP-HP, University of Paris Cité, Clichy, Paris, France, <sup>13</sup>Unit of Hepato-Pancreatic-Biliary Surgery, "F. Miulli" General Regional Hospital, 70021 Acquaviva Delle Fonti, Italy, <sup>14</sup>Service Chirurgie Digestive et Transplantation Hépatique, Hôpital Trousseau CHU, 37170 Tours, France, <sup>15</sup>Division of Hepatobiliary Surgical Oncology, Istituto Nazionale Tumori IRCCS Fondazione Pascale, 80131, <sup>16</sup>DIETI Department, University of Naples Federico II, 80100, Naples, <sup>17</sup>Department of General and Hepatobiliary Surgery, Liver Transplantation Center, San Camillo-Forlanini Hospital, Rome, <sup>18</sup>HPB Surgery and Liver Transplant Unit, University of Modena and Reggio Emilia, Modena, <sup>19</sup>General Surgery 1, Hepatobiliary Unit, IRCCS San Gerardo Dei Tintori, University of Milano-Bicocca, 20900, Monza, Italy, <sup>20</sup>Department of Digestive, Hepatobiliary and Endocrine Surgery, Hôpital Cochin, APHP Centre, 75014 Paris, France, and <sup>21</sup>University of Milan, Via Festa Del Perdono, 7, 20122, Milan, Italy

## Abstract

**Introduction:** Three-dimensional liver modeling can lead to substantial changes in choosing the type and extension of liver resection. This study aimed to explore whether 3D reconstruction helps to better understand the relationship between liver tumors and neighboring vascular structures compared to standard 2D CT scan images.

**Methods:** Contrast-enhanced CT scan images of 11 patients suffering from primary and secondary hepatic tumors were selected. Twenty-three experienced HBP surgeons participated to the survey. A standardized questionnaire outlining 16 different vascular structures (items) having a potential relationship with the tumor was provided. Intraoperative and histopathological findings were used as the reference standard. The proper hypothesis was that 3D accuracy is greater than 2D. As a secondary endpoint, inter-raters' agreement was explored.

**Results:** The mean difference between 3D and 2D, was 2.6 points (SE: 0.40; 95 % CI: 1.7–3.5;  $p < 0.0001$ ). After sensitivity analysis, the results favored 3D visualization as well (mean difference 1.7 points; SE: 0.32; 95 % CI: 1.0–2.5;  $p = 0.0004$ ). The inter-raters' agreement was moderate for both methods (2D:  $W = 0.45$ ; 3D:  $W = 0.44$ ).

**Conclusion:** 3D reconstruction may give a significant contribution to better understanding liver vascular anatomy and the precise relationship between the tumor and the neighboring structures.

Received 9 July 2023; accepted 1 October 2023

## Correspondence

Christian Cotsoglou, ASST-Brianza, Vimercate Hospital, Via Santi Cosma e Damiano 10, 20871, Vimercate, Italy. E-mail: [christian.cotsoglou@asst-brianza.it](mailto:christian.cotsoglou@asst-brianza.it)

## Introduction

One of the biggest challenges of modern medicine is to apply technology to deliver the best care service to patients. Advances in medical imaging and their integration have provided new opportunities to support surgeons in performing complex procedures and to enhance patient benefits and safety. Thanks to the use of three-dimensional reconstruction, it has become possible to make more and more like reality the complex anatomy of a specific body district.

In the history of 3D rendering, the target organs were especially those parenchymatous, such as the liver, kidney, and pancreas. The parenchyma is a specific tissue, which gives the organ its structural and functional characteristics surrounding and covering a multitude of vascular-biliary structures. For this reason, attention was focused specifically on hepato-bilio-pancreatic surgery (HPB), offering great advantages, especially in high-complexity liver surgery that involves vascular reconstruction.<sup>1,2</sup>

The practical applications of 3D technology can be divided into 3 macro-areas: preoperative surgical planning, guided intraoperative navigation, and the educational-informative field. Indeed, the 3D model is the most intuitive and simple method for communication with the patient and his family. In addition, this technology has a key role in the academic-educational field for the training of surgeons, thanks to a more direct and practical vision of the complexity of the procedure.<sup>3</sup>

Surgery still represents the cornerstone of the treatment of liver tumors. In patients suffering from these types of neoplasms, preoperative planning represents a crucial part of surgical management. Despite HPB-specialized radiologists being the more qualified healthcare professional to properly assess the anatomical relation of the tumor with neighboring vascular structures, experienced HPB surgeons are often required to evaluate CT images in order to adequately draw up a surgical plan, taking into account anatomical variants and the so-called “vanishing lesions” or “small invisible tumors”. These lesions are no longer viewable during intraoperative hepatic ultrasound, because of an impressive response to chemotherapy.<sup>4</sup>

3D reconstruction represents a tool that certainly cannot replace the radiologist’s information, but it can help in making more immediate and surgical-like preoperative planning. It does not only help to refine the surgical technique according to the anatomy of the patient, but in some cases, it allows a drastic change in the therapeutic strategy.<sup>5</sup>

Because evidence of its effect is still limited, the present study was designed to determine whether 3D reconstruction may help to understand the vascular invasion of hepatic tumors in the preoperative planning phase to take the best surgical decision for each patient.

## Methods

The primary aim of the study is to determine whether 3D reconstruction improves the understanding of the relationship between the tumor and the neighboring vascular structures compared to standard 2D CT scan images in complex liver surgery. The secondary endpoint was to assess inter-surgeons’ agreement.

The accuracy of the 2D and 3D methods was assessed using intraoperative and histopathologic findings as the reference standard. During surgery, intraoperative ultrasound scanning (IOUS) was always performed by the same surgeon.

### Pilot study

A small-scale preliminary study was conducted in order to verify the feasibility and the potential for a future full-scale project. Only one clinical case was evaluated by nine surgeons.

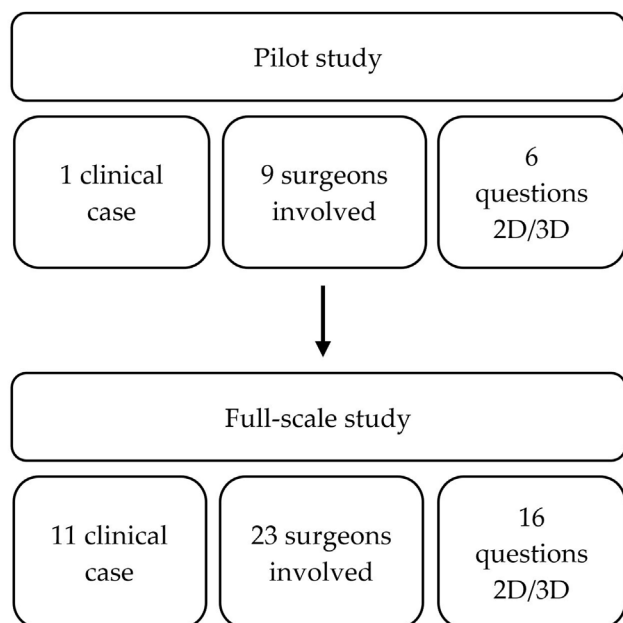
The raters were asked to answer six multiple-choice questions with one correct response. The questions concerned the invasion of some of the principal vascular hepatic structures (i.e. the middle hepatic vein, vena cava, left portal vein, right anterior portal vein, right anterior biliary tract, and right hepatic artery) based on the critical anatomical relationship with the tumor.

Detailed information regarding the results of the pilot study is reported in supplementary materials.

Given the promising results of the pilot study, we decided to proceed to the full-scale survey enlarging both the sample size of clinical cases and the number of raters (Fig. 1).

### 3D model generation and design of the full-scale survey

To explore more thoroughly the results of the pilot study, a survey with 11 clinical cases was conducted. All of them were judged as complex liver tumors according to different definitions reported in the literature<sup>6–9</sup> by a panel of three experienced HPB surgeons at our institution. All clinical cases were retrospectively selected, and contrast-enhanced CT (Ce-CT) scan images were downloaded anonymously from ASST-Brianza, Vimercate Hospital PACS system.



**Figure 1** Design of the study

CT images were acquired through cross-sectional scanning, with tube voltage based on the patient's size and weight. The slices' thickness varied from 0.625 up to 2.5 mm, with a large scan field and a standard reconstruction algorithm. Iodine medium was administered intravenously by rapid bolus injection (1.0–2.0 ml/kg at 4.5–5 ml/s) and arterial, portal, and delayed scans were performed according to our standard protocol. The DICOM images were processed to obtain a full virtual 3D model thanks to the close collaboration of different professional figures such as the radiologist, the surgeon, and a biomedical engineer as recommended by the most recent guidelines.<sup>10</sup> The 3D models were generated by passing through two different phases. The first one was completed automatically using neural networks. Feature extractions can be performed by machine learning algorithms, able to learn patterns from existing data and apply them to new data. Neural networks are based on multiple layers of transformations (convolution), which are applied on top of each other to extract a progressively more sophisticated representation of the input. The learning method is based on the generation of an error signal that measures the difference between the predictions of the network and the desired values and then the usage of this error signal to change the weights in order to make predictions more accurate. Finally, the output layer combines those features to make predictions, such as to identify different anatomical structures.<sup>11</sup>

Since the neural networks were not able to define all anatomical structures, the segmentation was manually post-processed using specific, open-source software (3D Slicer 5.0.2).<sup>12–14</sup> The software is built on a modular architecture: all labels from the automatic phase were uploaded and the post-processing was performed via Segment Editor Module to

obtain a more realistic and accurate 3D model.<sup>12</sup> Fig. 2 shows an example of the two phases process.

The number of operations made during the post-processing phase depended on the complexity of the clinical case. If the tumor was very large and it deformed neighboring vascular structures, neural networks struggled more to correctly determine even the main anatomical structures. Hence, meticulous and accurate corrections were needed to get a reliable 3D model. 3D renderings were then exported from the software in.gITF format and uploaded on an online interactive platform easily available for consultation.<sup>15</sup>

To benchmark the quality of each final model we referred to the quality control system of 3D visualization technology (3DVT) proposed by Fang et al.<sup>10</sup> A score of 15 or above was recognized as desirable.

Only experienced HPB surgeons, who performed at least 150 complex liver resections, were invited to participate in the present multicentric, international survey. The survey was structured so that for each case always the same questions were posed. By doing so, the same vascular structures were always analyzed, and not only those characterizing each specific clinical case. This also allowed us to standardize and better compare the results. The template of questions used in the survey for each clinical case is reported in supplementary materials.

As in the pilot study, five multiple-choice answers were given: “no vascular invasion”, “tangential infiltration”, “circumferential infiltration”, “vascular deformation”, and “not determinable”. Circumferential infiltration was defined as the vascular structure completely surrounded by the tumor or the vessel is wrapped around by the tumor for more than 180°. Tangential infiltration described the tumor encasing the vessel for less than 180°. Vascular deformation was characterized by the distortion of the vessel.

The survey was managed using an online platform (<https://www.sondaggio-online.com/>). Before answering, each participant downloaded 2D CT images in DICOM format. It was mandatory to answer all questions. Each question had one correct answer. After completing the 2D survey, the participant moved to the 3D questionnaire. The rater could freely rotate and zoom the rendering and turn on/off the visualization of certain parts.

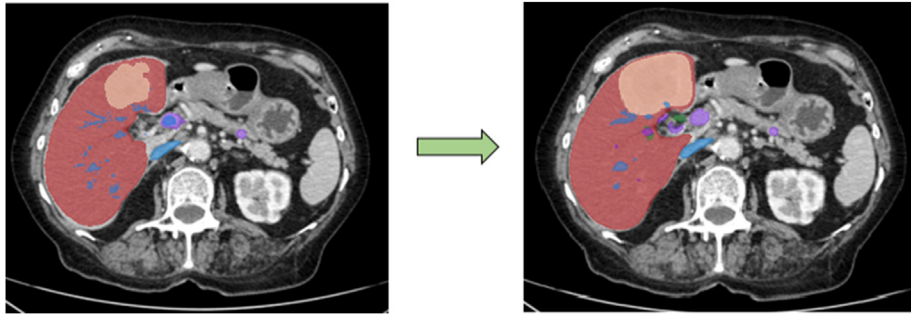
While viewing the 3D model, each rater completed this part of the survey as well. The participant could always consult 2D images but modifying the answers of the 2D questionnaire was no longer allowed at this point.

### Statistical analysis

For each included patient  $i$ , the surgeon  $j$  was asked to answer a standardized questionnaire outlining 16 different vascular structures (items) potentially invaded by the tumor.

A score of 1 was assigned for each correct evaluation of each item, and the sum of correct assessments for all items was computed both for 2D and 3D.

The primary measure of interest is the difference  $\delta_{ij}$  between the overall score obtained with 3D and the overall score obtained



**Figure 2** Same slice of a CT image segmented at the end of the first automatic phase (left) and manually post-processed (right)

with 2D. To account for clustering induced by each surgeon evaluating the same set of patients, the following linear crossed random-effects model was fitted<sup>16</sup>:

$$\delta_{ij} = \alpha + b_i + c_j + \varepsilon_{ij}$$

With  $b_i \sim N(0, \sigma_b^2)$  the patient random-effect,  $c_j \sim N(0, \sigma_c^2)$  the surgeon random-effect, and  $\varepsilon_{ij} \sim N(0, \sigma_\varepsilon^2)$  is the residual error.

The main assumption was that 3D accuracy is greater than 2D. Hence, the null hypothesis  $H_0$  was that the accuracy is the same with the two methods. The model allows us to estimate  $\alpha$  (i.e. the average  $\delta_{ij}$ ) and its standard error (SE), and to properly test the primary null hypothesis:  $H_0: \alpha = 0$ . In the evaluation of  $H_0$ , a two-sided p-value less than 0.05 was considered statistically significant, suggesting that the average difference between the two approaches is greater than 0.

Sensitivity analysis was conducted after re-categorizing the answers to each question as follows:

- 1 “no vascular invasion” and “vascular deformation” were grouped as “no invasion”;
- 2 “tangential” and “circumferential infiltration” were grouped as “vascular infiltration”;
- 3 “not determinable” was left as it was.

Only few cases focused on the relationship between the tumor and biliary vessels, therefore, biliary anatomy was reconstructed in the 3D model only in 3 out of 11 cases (when the biliary tree was dilated due to Klatskin tumors). To explore the goodness of our findings the analysis was then repeated after excluding the questions regarding biliary anatomy.

As a secondary endpoint, the inter-surgeon agreement was measured by Kendall’s W correlation coefficient,<sup>17</sup> and interpreted as follows: <0.20 poor agreement, 0.21–0.40 fair agreement, 0.41–0.60 moderate agreement, 0.61–0.80 good agreement and 0.81–1.00 very good agreement.

The SAS MIXED procedure was used to estimate the random-effects model. To calculate Kendall’s W the macro SAS MAGREE was used.<sup>18</sup>

For the sample size and power calculations, we assumed, as the alternative hypothesis  $H_1$ ,  $\alpha = 2$ , indicating a clinically significant improvement of 3D reconstruction over 2D imaging. The inter-surgeon agreement was assumed to be good ( $W = 0.70$ ).

Under these assumptions, 11 patients, each examined by at least 10 surgeons, were required to achieve at least 80 % power to reject the null hypothesis.

Sample size and power calculations were based on a simulation study performed in SAS.

## Results

### General, non-comparative results

Eight out of eleven 3D models scored  $\geq 15$  points at the quality control system of 3DVT. Twenty-three experienced HBP surgeons agreed to participate in the survey, exceeding the planned sample size of ten. Seventeen out of 23 surgeons fully completed the survey. A total of 3232 answers was given. The results of both the 2D and 3D questionnaires are summarized in Table 1 and graphically displayed in Fig. 3. Further details are reported in supplementary materials (Table S1). A detailed analysis of some emblematic clinical cases is reported in supplementary materials as well.

### Primary endpoint

The mean difference  $\delta$  between 3D and 2D, calculated on all  $i$  patients for all  $j$  surgeons, was 2.6 points (SE: 0.40, 95 % CI: 1.7–3.5;  $p < 0.0001$ ), indicating that the 3D model is more accurate than standard 2D CT scan images for understanding the relationship between the tumor and the neighboring vascular structures in complex liver resections. Surgeons who did not evaluate all 11 clinical cases were also considered in this analysis.

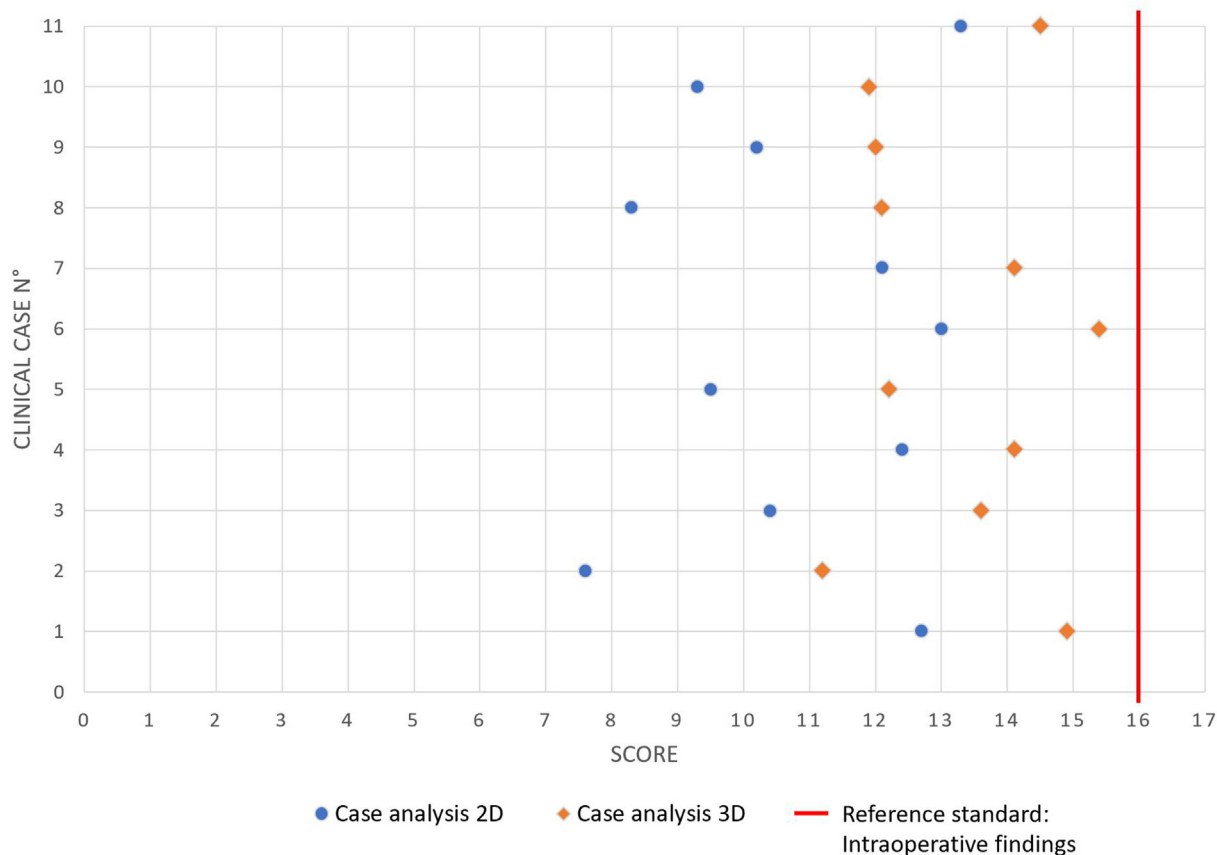
After sensitivity analysis, the mean difference  $\delta$  between 3D and 2D was 1.4 points (SE: 0.26, 95 % CI: 0.8–1.9;  $p = 0.0004$ ).

Furthermore, after excluding questions regarding biliary anatomy (n. 13, 14, 15, 16), the results did not change substantially: the mean difference  $\delta$  between 3D and 2D was 1.7 points (SE: 0.32; 95 % CI: 1.0–2.5;  $p = 0.0004$ ).

The average 2D concordance with surgery, calculated on all patients for all surgeons, was 8.2 points (SE: 0.64; 95 % CI:

**Table 1** Average score of concordance between 2D and surgery and between 3D and surgery per patient. CRLM: colorectal liver metastasis; UESL: undifferentiated embryonal sarcoma of the liver; NETLM: neuroendocrine tumor liver metastasis; HH: hepatic hemangioma; ICC: Intrahepatic cholangiocarcinoma

Patient #	Type of tumor	N° of tumors	N of surgeons who completed the survey	Agreement 2D – ref. standard mean (min, max)	Agreement 3D – ref. standard mean (min, max)	Agreement difference 3D – 2D mean (min, max)
1	Klatskin	1	23	12.7 (2, 16)	14.9 (10, 16)	2.3 (-3, 12)
2	Klatskin	1	20	7.6 (2, 15)	11.2 (6, 15)	3.6 (0, 8)
3	Klatskin	1	19	10.4 (2, 14)	13.6 (5, 16)	3.3 (0, 9)
4	CRLM	1	18	12.4 (8, 16)	14.1 (10, 16)	1.7 (-1, 6)
5	CRLM	11	18	9.5 (5, 12)	12.2 (8, 15)	2.7 (-1, 9)
6	CRLM	1	17	13.0 (9, 15)	15.4 (11, 16)	2.4 (0, 5)
7	HCC	1	18	12.1 (9, 15)	14.1 (10, 16)	1.9 (-1, 7)
8	UESL	1	18	8.3 (4, 12)	12.1 (5, 16)	3.8 (1, 10)
9	NETLM	1	17	10.2 (5, 13)	12.0 (8, 15)	1.8 (-2, 6)
10	HH	1	17	9.3 (2, 14)	11.9 (7, 16)	2.6 (-2, 13)
11	ICC	1	17	13.3 (5, 16)	14.5 (8, 16)	1.2 (-4, 6)



**Figure 3** Graphical representation of the primary endpoint

6.8–9.7); the mean 3D concordance with surgery, was 10.1 points (SE: 0.37; 95 % CI: 9.3–10.9). The agreement on each item is represented in [Table 2](#).

### Secondary endpoint

Only the 17 surgeons who evaluated all clinical cases were included in this analysis, as the calculation of Kendall's W



**Table 2** Agreement for each parameter evaluated

Vascular invasion parameters	Agreement 2D-ref. standard (%)	Agreement 3D-ref. standard (%)	Agreement difference in favor of 3D (%)
Right hepatic vein	74.3	86.6	12.4
Middle hepatic vein	59.6	80.8	21.2
Left hepatic vein	82.7	92.1	9.4
Cava vein	73.3	82.2	8.9
Right principal portal vein	72.8	85.1	12.4
Right anterior portal vein	68.8	83.2	14.4
Right posterior portal vein	62.9	78.7	15.8
Left portal vein	89.6	96.0	6.4
Right principal hepatic artery	73.9	85.2	11.3
Right anterior hepatic artery	61.1	79.3	18.2
Right posterior hepatic artery	52.7	75.9	23.2
Left hepatic artery	86.6	95.5	8.9

requires that all raters assessed the same number of individuals. The inter-raters' agreement was moderate for both methods (2D:  $W = 0.45$ ; 95 % CI: 0.33–0.57. 3D:  $W = 0.44$ ; 95 % CI: 0.30–0.58). After sensitivity analysis, the results did not change significantly (2D:  $W = 0.43$ ; 95 % CI: 0.31–0.55. 3D:  $W = 0.41$ ; 95 % CI: 0.25–0.56).

## Discussion

One of the toughest tasks every HPB surgeon struggles the most with is represented by the need to mentally reconstruct the spatial relationship between the tumor and the blood/biliary vessels neighboring it. Surgical experience plays a cornerstone role in completing this mission. Before the advent of digital technologies capable of providing three-dimensional reconstructions of parenchymatous organs, conventional radiology has been representing the only way to achieve this important step of the preoperative workout. In such a setting, the close and synergic interaction between HPB surgeons and radiologists is crucial. However, the interpretation of the images may be substantially different between these two professionals. The expert HPB radiologist can provide a detailed portrait of the anatomical relationship between the tumor and the surrounding structures with remarkable accuracy, but what the HPB surgeon needs is a “dynamic vision” to predict the feasibility of specific surgical maneuvers in a three-dimensional representation.

3D technologies allow nowadays for more precise, reliable, and repeatable liver models that, also through 3D printing, can be freely rotated and moved to obtain a better and more accurate sight of liver anatomy from different angles. This technology provides a more intuitive vascular model and correlates more closely with the anatomy that the surgeon will observe in the operating theater. Furthermore, it also covers a key role from an educational point of view for residents and young HPB surgeons.

Many recent scientific reports focused on the ability of 3D models to lead a change in the surgical plan.<sup>19–22</sup> A patient-level meta-analysis published by Zhang et al.<sup>23</sup> demonstrated how the use of 3D visualization technology in liver surgery led to significantly shorter operative times, lower intraoperative blood losses, perioperative transfusional need, postoperative complication rate, and a smaller difference between the predicted and actual resected liver volume compared to standard 2D images.

On the other hand, only a few works focused on *if* and *how much* 3D rendering increases the understanding of liver surgical-oncological anatomy compared to 2D, outside an educational setting. The present study demonstrates that 3D reconstructions provide anatomical information more like the actual surgical reality compared to standard 2D CT images. Even though the aim of our study was not to explore a hypothetical 3D-driven change in surgical planning, this can make a difference when choosing the extent of liver resection, for example shifting from a vascular R1 wedge resection to a major, anatomical hepatectomy in case of tumors located close to principal hepatic veins or portal branches. In some of the clinical cases used for the survey (Supplementary materials – Clinical cases #4 and #8), with the aid of the 3D reconstruction we understood in advance the technical impossibility of performing specific surgical movements, for example, the liver hanging maneuver. This allowed us to avoid dangerous attempts dictated only by the intraoperative tactile perception, starting directly with a posterior approach, saving time and reducing the risk of sudden bleeding.<sup>24</sup>

3D rendering may be also extremely helpful when approaching colorectal liver metastases having a complete shrinking after systemic chemotherapy, the so-called “disappearing liver metastases” (DLM)<sup>25,26</sup> (Supplementary materials – Clinical case #5). These lesions may no longer be detectable during intraoperative hepatic ultrasound. In such a scenario, 3D models built on CeCT scans performed before and after the systemic

treatment, may represent the only tool guiding liver resection, especially if a fiducial has not been placed before starting chemotherapy.

The questions of our survey were chosen to be the same across all clinical cases, allowing for a standardized comparison and statistical analysis. However, for each clinical case, only a few were the key questions to decide the most suitable therapeutic strategy for the patient. 3D models resulted particularly useful in answering these questions, difficult to be interpreted correctly only with 2D images but of paramount importance for correct preoperative surgical planning.

In this regard it is worth underlining how a multidisciplinary approach is of paramount importance to achieve a high-end tridimensional reconstruction, avoiding deviations from reality that could increase the risk of adverse clinical events. Indeed, the engineer can translate into technical and numerical terms the radiologist's and surgeon's perception and interpretation of the anatomical structures.<sup>10</sup> Such cooperation between different professionals represents the basis of a "3D team" that underlines how the final model does not only add a third dimension but represents the result of a fine and accurate interpretation of clinical images that today cannot ignore human intervention.

The anatomy of intra- and extrahepatic bile ducts deserves special consideration. 3D models breed from bi-dimensional images and if bile ducts are not dilated, they will not be detectable on conventional imaging, nor the 3D reconstruction. However, when they are clearly dilated, as in the case of Klatskin tumors, the model can be used as a 3D cholangiography: the dynamic perception of biliary anatomy, especially intrahepatic ramifications, can help the surgeon to tailor the resection, including, for instance, some ducts in the bilio-digestive anastomosis. Furthermore, in a recent report, Ruzzenente et al. demonstrated how 3D reconstruction can give substantial help in recognizing vessels' anomalies.<sup>22</sup>

Our study is burdened by some limitations. Not all 3D models were built using CT images with the same thickness. Moreover, since all clinical cases were collected retrospectively, thin-layer images (1 mm thickness or below) were not available for all patients. More in general, although most of the clinical cases scored adequately at the quality control system of 3DVT, few cases did not match the standards. Another pitfall of our research is that 17 out of 23 raters fully completed the survey. However, to mitigate the effect of such a bias, sensitivity analysis was conducted to obtain more robust results.

Finally, the inter-raters agreement was only moderate, but interestingly, it did not depend on the evaluation method used (2D vs 3D). This means that further variables we were not able to detect and parametrize, other than visualization technology and surgeon's experience, may play a determinant role in the interpretation of clinical images.

On the other hand, to the best of our knowledge, the present study is the first one exploring through a multicentric, international survey the ability of 3D rendering in improving the

understanding of the anatomical relationship between hepatic tumors and blood/biliary vessels. In the present study, only experienced HPB surgeons, who performed a remarkable amount of complex liver resections, took part in the survey. At a first glance, this factor may be seen as a source of variability, but it actually contributed to obtaining more reliable and robust results. Our study did not focus on a possible change of preoperative strategy on purpose; indeed, the type and extent of hepatic resection depend on many different variables. Based on this consideration, we decided to focus instead on a more objective parameter, such as the anatomical relationship of the tumor with vascular structures to explore the effectiveness of 3D modeling.

## Conclusions

The results of the present international multicentric survey underlined how 3D reconstruction may give a significant contribution to better understanding liver vascular anatomy and the precise relationship between the tumor and the neighboring structures. A larger-scale survey, with a greater amount of clinical cases, and based on high-quality models would be interesting to confirm our findings.

## Funding

The Authors declare that no specific funding was received for the present study.

## Acknowledgments

None.

## Conflict of interest

None to declare.

## References

- Pietrabissa A, Marconi S, Negrello E, Mauri V, Peri A, Pugliese L et al. (2020) An overview on 3D printing for abdominal surgery. *Surg Endosc* 34:1–13. <https://doi.org/10.1007/s00464-019-07155-5>.
- Huber T, Huettl F, Saalfeld P, Chheang V, Paschold M, Lang H et al. (2019) Entwicklung eines interaktiven multi-user virtual reality moduls Am beispiel der leberresektion. vol. 57. In: *74 Jahrestagung der Dtsch Gesellschaft für Gastroenterol Verdauungs- und Stoffwechselkrankheiten mit Sekt Endosc – 13 Herbsttagung der Dtsch Gesellschaft für Allg und Visz Gem mit den Arbeitsgemeinschaften*. <https://doi.org/10.1055/s-0039-1695378>, 2020–1.
- Huettl F, Saalfeld P, Hansen C, Preim B, Poplawski A, Kneist W et al. (2021) Virtual reality and 3D printing improve preoperative visualization of 3D liver reconstructions—results from a preclinical comparison of presentation modalities and user's preference. *Ann Transl Med* 9. <https://doi.org/10.21037/atm-21-512>, 1074–1074.
- Banz VM, Müller PC, Tinguely P, Inderbitzin D, Ribes D, Peterhans M et al. (2016) Intraoperative image-guided navigation system: development and applicability in 65 patients undergoing liver surgery. *Langenbeck's Arch Surg* 401:495–502. <https://doi.org/10.1007/s00423-016-1417-0>.

5. Wang XD, Wang HG, Shi J, Duan WD, Luo Y, Ji W Bin *et al.* (2017) Traditional surgical planning of liver surgery is modified by 3D interactive quantitative surgical planning approach: a single-center experience with 305 patients. *Hepatobiliary Pancreat Dis Int* 16:271–278. [https://doi.org/10.1016/S1499-3872\(17\)60021-3](https://doi.org/10.1016/S1499-3872(17)60021-3).
6. Bittoni A, Scartozzi M, Giampieri R, Faloppi L, Maccaroni E, Del Prete M *et al.* (2013) The tower of babel of liver metastases from colorectal cancer: are we ready for one language? *Crit Rev Oncol Hematol* 85. <https://doi.org/10.1016/j.critrevonc.2012.08.005>.
7. Zhao D, Lau WY, Zhou W, Yang J, Xiang N, Zeng N *et al.* (2018) Impact of three-dimensional visualization technology on surgical strategies in complex hepatic cancer. *Biosci Trends* 12. <https://doi.org/10.5582/bst.2018.01194>.
8. Lopez-Lopez V, Robles-Campos R, García-Calderon D, Lang H, Cugat E, Jiménez-Galanes S *et al.* (2021) Applicability of 3D-printed Models in hepatobiliary surgery: Results from “LIV3DPRINT” multicenter study. *HPB* 23. <https://doi.org/10.1016/j.hpb.2020.09.020>.
9. Huber T, Huettl F, Tripke V, Baumgart J, Lang H. (2021) Experiences with three-dimensional printing in complex liver surgery. *Ann Surg* 273. <https://doi.org/10.1097/SLA.0000000000004348>.
10. Fang C, An J, Bruno A, Cai X, Fan J, Fujimoto J *et al.* (2020) Consensus recommendations of three-dimensional visualization for diagnosis and management of liver diseases. *Hepatol Int* 14:437–453. <https://doi.org/10.1007/s12072-020-10052-y>.
11. Russell HT, Stephane L, Grigore B, Mosges R. (1995) *Computer-integrated surgery*.
12. Slicer-Community. (2019) *3D slicer Documentation\_20210513*. *3D slicer*, pp. 2–48.
13. Kikinis R, Pieper SD, Vosburgh KG. (2014) *3D slicer: a platform for subject-specific image analysis, visualization, and clinical support. Intraoperative imaging and image-guided therapy*. [https://doi.org/10.1007/978-1-4614-7657-3\\_19](https://doi.org/10.1007/978-1-4614-7657-3_19).
14. Fedorov A, Beichel R, Kalpathy-Cramer J, Finet J, Fillion-Robin J-C, Pujol S *et al.* (2012) 3D slicer as an image computing platform for the quantitative imaging network. *Magn Reson Imaging* 30:1323–1341. <https://doi.org/10.1016/j.mri.2012.05.001>.
15. Kovacs V. Online 3D viewer. Available at: <https://3dviewer.net/index.html>.
16. Snijders T, Bosker R. (1999) *Multilevel analysis: an introduction to basic and advanced multilevel modeling*. Sage.
17. Kendall MG, Smith BB. (1939) The problem of  $\$m\$$  rankings. *Ann Math Stat* 10. <https://doi.org/10.1214/aoms/1177732186>.
18. Gwet K. (2002) Computing inter-rater reliability with the SAS system. *Stat Methods Inter-rater Reliab Assess* 3:1–16.
19. Fang CH, Tao HS, Yang J, Fang ZS, Cai W, Liu J *et al.* (2015) Impact of three-dimensional reconstruction technique in the operation planning of centrally located hepatocellular carcinoma. *J Am Coll Surg* 220. <https://doi.org/10.1016/j.jamcollsurg.2014.09.023>.
20. Mise Y, Hasegawa K, Satou S, Shindoh J, Miki K, Akamatsu N *et al.* (2018) How has virtual hepatectomy changed the practice of liver surgery? *Ann Surg* 268. <https://doi.org/10.1097/sla.0000000000002213>.
21. Nakayama K, Oshiro Y, Miyamoto R, Kohno K, Fukunaga K, Ohkohchi N. (2017) The effect of three-dimensional preoperative simulation on liver surgery. *World J Surg* 41. <https://doi.org/10.1007/s00268-017-3933-7>.
22. Ruzzenente A, Alaimo L, Conci S, De Bellis M, Marchese A, Ciangherotti A *et al.* (2023) Hyper accuracy three-dimensional (HA3D™) Technology for planning complex liver resections: a preliminary single center experience. *Updates Surg* 75:105–114. <https://doi.org/10.1007/s13304-022-01365-8>.
23. Zhang S, Huang Z, Cai L, Zhang W, Ding H, Zhang L *et al.* (2021) Three-dimensional versus two-dimensional video-assisted hepatectomy for liver disease: a meta-analysis of clinical data. *Wideochirurgia I Inne Tech Maloinwazyjne* 16. <https://doi.org/10.5114/WIITM.2020.100678>.
24. Coppa J, Citterio D, Cotsoglou C, Germini A, Piccioni F, Sposito C *et al.* (2013) Transhepatic anterior approach to the inferior vena cava in large retroperitoneal tumors resected en bloc with the right liver lobe. *Surgery (United States)* 154. <https://doi.org/10.1016/j.surg.2013.05.027>.
25. Tsilimigras DI, Ntanasis-Stathopoulos I, Paredes AZ, Moris D, Gavriatopoulou M, Cloyd JM *et al.* (2019) Disappearing liver metastases: a systematic review of the current evidence. *Surg Oncol* 29. <https://doi.org/10.1016/j.suronc.2019.02.005>.
26. Granieri S, Cotsoglou C, Bonomi A, Salvatore L, Filippi R, Nigro O *et al.* (2022) Conversion strategy in left-sided RAS/BRAF wild-type metastatic colorectal cancer patients with unresectable liver-limited disease: a multicenter cohort study. *Cancers (Basel)* 14:5513. <https://doi.org/10.3390/cancers14225513>.

#### Appendix A. Supplementary data

Supplementary data to this article can be found online at <https://doi.org/10.1016/j.hpb.2023.10.003>.